Facial Gender Surgery: Systematic Review and Evidence-Based Consensus Guidelines from the International Facial Gender Symposium

Devin Coon, M.D., M.S.E.
Jens Berli, M.D.
Norah Oles, B.S.
Sol Mundinger, M.D., M.B.A.
Kate Thomas, Ph.D.
Toby Meltzer, M.D.
Carrie Houssock, M.D.
Thomas Satterwhite, M.D.
Shane Morrison, M.D., M.S.
Carlos Bailón, M.D.
Thiago Tenório, M.D.
Daniel Simon, D.M.D.
Fermín Capitán-Cañadas, Ph.D.
Luis Capitán, M.D., Ph.D.

Baltimore and Owings Mills, Md.; Portland, Ore.; New Orleans, La.; Scottsdale, Ariz; San Francisco, Calif.; Seattle, Wash.; and Marbella, Málaga, Spain

Background: Increasing societal acceptance of transgender people has led to broader availability of gender surgery and rapid growth in transition-related operations. Facial gender surgery aims to modify patients' facial features to be more congruent with their physical expression of gender, reducing gender dysphoria and improving quality of life. Growth in research and technique evolution has not kept pace with growth in clinical volume. Therefore, the first International Facial Gender Symposium was held at Johns Hopkins University in 2019, convening surgeons who perform facial gender surgery to share ideas and assess the state of clinical evidence.
Methods: To review the literature on facial gender surgery, the authors developed a search strategy for seven electronic databases (PubMed, PsycINFO, Embase, CINAHL, Web of Science, Cochrane, and Gender Studies) through May of 2019, following Preferred Reporting Items for Systematic Reviews and Meta-Analyses systematic review guidelines.
Results: Based on the English language literature and clinical experience, the authors suggest guidelines for screening, management, and appropriate surgical technique for patients undergoing facial gender surgery. They highlight facial gender surgery as a medically necessary intervention and identify shortcomings in current guidelines.
Conclusions: Facial gender surgery represents a complex array of craniofacial and soft-tissue procedures that require application of advanced skills and decision-making. Facial gender operations are not cosmetic, are medically necessary, and require development of new CPT codes specific to facial gender surgery. It is imperative to create educational programs and methods to define sufficient training for facial gender surgery surgeons. Research priorities include better procedural outcomes data, more quality-of-life studies, and insight into variation in both patient and procedural subgroups. (*Plast. Reconstr. Surg.* 149: 212, 2022.)

PATIENT SAFETY

It is estimated that over 1 million individuals in the United States are transgender, and these numbers are growing.[1] Rapidly growing societal acceptance has led to subsequent increases in gender-affirming operations. Facial gender surgery, also called facial gender-confirmation surgery,[2]

From the Departments of Plastic and Reconstructive Surgery and Psychiatry, Johns Hopkins University School of Medicine; Johns Hopkins Center for Transgender Health, Johns Hopkins Hospital; Division of Plastic and Reconstructive Surgery, Oregon Health & Science University; Division of Plastic and Reconstructive Surgery, Louisiana State University Medical Center and Children's Hospital of New Orleans; The Meltzer Clinic PC; James Vogel Plastic Surgery; Align Surgical Associates, Inc.; Division of Plastic Surgery, Department of Surgery, University of Washington School of Medicine; and The Facialteam Group, HC Marbella International Hospital.
Received for publication November 17, 2019; accepted May 20, 2021.

DOI: 10.1097/PRS.0000000000008668

Disclosure: *The authors have no financial interest to declare in relation to the content of this article.*

Related digital media are available in the full-text version of the article on www.PRSJournal.com.

By reading this article, you are entitled to claim one (1) hour of Category 2 Patient Safety Credit. ASPS members can claim this credit by logging in to PlasticSurgery.org Dashboard, clicking "Submit CME," and completing the form.

facial gender-affirmation surgery, or facial feminization surgery, aims to modify patients' facial features to be more congruent with physical expression of gender, reducing gender dysphoria.[3]

Initial surgical concepts were largely pioneered by Ousterhout in the 1980s as an extension of craniomaxillofacial surgery principles.[4] Since then, the scope of the field has broadened substantially and represents a fusion of techniques and principles from craniomaxillofacial surgery, aesthetic surgery, and nonsurgical modalities. Historically, the great majority of facial gender surgery has been performed only at a handful of high-volume centers worldwide. The scarcity of surgeons performing facial gender surgery and the crossing of specialty lines (plastic surgery, oral maxillofacial surgery, and otolaryngology) has led to a persistently isolated field, even at transgender-focused meetings such as the World Professional Association for Transgender Health. There has never been an opportunity for facial gender surgery surgeons to come together to discuss techniques and innovations.

For these reasons, the necessity of convening surgeons who perform facial gender surgery became increasingly clear. On July 26 through 27, 2019, the first International Facial Gender Symposium was held at Johns Hopkins University as a 2-day symposium. Over 40 surgeons attended, representing the United States, Europe, South America, and Australia.

Based on the discussions held at the conference, a list of high-priority areas was formulated and the symposium faculty collaborated to analyze the salient issues. The specific recommendations and position statements presented in this article represent the panel's expert opinion based on collective experience and review of current evidence.

CURRENT EVIDENCE

Literature Search

In collaboration with a medical informationist at Johns Hopkins, we developed a comprehensive search strategy for seven electronic databases (PubMed, PsycINFO, Embase, CINAHL, Web of Science, Cochrane, and Gender Studies) for relevant studies from inception through May of 2019. All surgical procedures for the stated purpose of gender affirmation were included. Using DistillerSR, two independent reviewers reviewed references at the title, abstract, and full-text levels in duplicate. Case studies ($n < 5$), letters, textbook chapters, and articles with no English translation were excluded. References without any quantitatively reported outcomes were also excluded. The Preferred Reporting Items for Systematic Reviews and Meta-Analyses guidelines were followed (Fig. 1). (**See Document, Supplemental Digital Content 1**, which shows the literature search methods, ***http://links.lww.com/PRS/E789***. **See Document, Supplemental Digital Content 2**, which shows the literature search terms, ***http://links.lww.com/PRS/E790***. **See Document, Supplemental Digital Content 3**, which shows the Preferred Reporting Items for Systematic Reviews and Meta-Analyses checklist, ***http://links.lww.com/PRS/E791***.)

Overall Facial Gender Surgery Evidence

Twenty-one articles on facial gender surgery were identified within this cohort, with 76 percent (16 studies) including some form of patient-centered outcomes. Most pointed to high rates of satisfaction and improved quality of life in patients who have undergone facial gender surgery; however, many cases were small cohorts or lacked effective instruments for assessing patient-reported outcomes. It should also be noted that nearly all articles originated from the same few experienced high-volume authors.

The procedural distribution of the 21 included articles was as follows: 62 percent (13 studies) included upper face procedures, primarily forehead; 66 percent (14 studies) described midface procedures, including rhinoplasty; 52 percent (11 studies) described lower face procedures, primarily genioplasty and mandibular osteotomy; and two studies did not specify.[3–22] All 19 studies that specified procedure type included bony procedures or combined bony/soft-tissue procedures.

Satisfaction was high across all procedures, with few complications reported. Seven studies (33 percent) reported any complication, and these were mostly minor. Five studies (24 percent) reported whether patients sought revision surgery; 19 of 467 patients (4 percent) underwent revision for persistent infection, unmet expectations, nasal valve reconstruction, and bony nonunion. Overall satisfaction with the result of surgery occurred in 534 of 550 patients (97 percent) (11 studies). Three additional studies reported overall satisfaction to be high but failed to report specifics. Seven studies (33 percent) specifically assessed patients' perceptions of their postsurgical face and change in self-perceived femininity; 235 of 295 patients (80 percent) reported feeling more feminine as a result of surgery (Table 1).

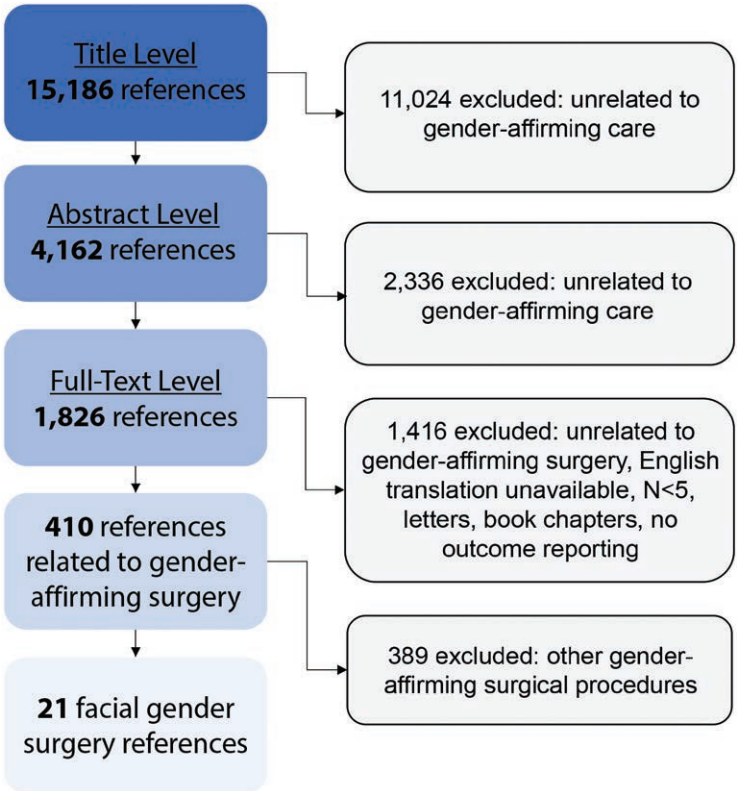

Fig. 1. Literature search. Flow diagram of literature search and reference screening.

Focus Articles

Ainsworth and Spiegel, 2010

The study by Ainsworth and Spiegel[3] was a retrospective cross-sectional study that enrolled 247 participants, of whom 75 underwent facial gender surgery and 172 did not. Outcomes included a demographics survey, the 36-Item Short-Form Health Survey version 2, and a facial gender surgery outcomes evaluation. The latter was a six-question Likert scale–type patient-reported instrument measuring self-image and social aspects of facial appearance (e.g., "My friends and loved ones perceive my face as feminine," "In public I am confident my facial appearance is perceived as feminine") and scored from 0 to 100 adapted from an instrument developed in 2002.[23] Patients who had undergone facial gender surgery scored 76, whereas those without facial surgery scored 44, a highly significant difference. The 36-Item Short-Form Health Survey mental component, which examines quality-of-life related to mental health, showed significantly lower scores for patients without surgical intervention. Limitations of this study include the case-control type design. However, the data for facial self-image and perceived femininity improvements from facial gender surgery are relatively compelling.

Morrison and Capitán, 2019

The study by Morrison and Capitán[24] was a prospective, multicenter cohort study. The Facial Feminization Surgery Outcome Instrument, the same instrument used in the study by Ainsworth and Spiegel, was administered preoperatively and at short-term and long-term postoperative time points (<1 month and >6 months). Sixty-six consecutive patients were enrolled. There was an average of 4.2 procedures per patient, and the most common procedures were frontal sinus setback/forehead contouring (89.4 percent), genioplasty (68.2 percent), rhinoplasty (65.2 percent), and mandibular contouring (59.1 percent).

The Facial Feminization Surgery Outcome score improved significantly at all time points, consistent with previous studies (Table 2). Photographic measurements and objective cephalometric measures were significantly more feminine after surgery. As a prospective cohort study demonstrating significant changes in both observer perceptions of facial femininity and in patient-reported impact of facial appearance on life and mental health, this article represents strong evidence for the medical necessity of facial gender surgery.

Table 1. Facial Gender Surgery Outcomes: Current Literature

First Author and Year	Study Type	Evidence Level	No. of Patients	Procedures Performed	Observer-Graded Appearance	Patient-Reported Satisfaction	Outcome Instrument	Complications	Revision Operations	Follow-Up (range or mean)
Gupta, 2019	Case series	IV	25	All: Forehead contour, rhinoplasty, mandibular contour, face lift, brow lift, cheek implants; lip lift (n = 24), fat grafting (n = 19), chondrolaryngoplasty (n = 14), earlobe reconstruction/otoplasty (n = 4), forehead lipoma (n = 2)	—	All satisfied	—	1 intraoral wound dehiscence, 2 cheek implant infection	—	20.58 wk
Mommaerts, 2019	Case series	IV	5	Mandibular osteotomy	Postoperative imaging showed "excellent bony and acceptable periodontal conditions"	All satisfied	CT imaging	"No dental, periodontal, or TMJ-related complications were encountered"	—	6–13 mo
Raffaini, 2019	Case series (consecutive)	IV	9	"Full FFS" with implication that upper, middle, and lower thirds of face modified	9/9 improved appearance	All satisfied	—	0 infection/dehiscence, 1 numbness at hairline	—	—
Isung, 2017	Case series	IV	10	Operations not specified	—	Postoperatively: TCS score improved (appearance congruence subscore also increased), significant improvement in BIS postoperatively	TCS, BIS, HAD, SDS	—	—	—
Lipschitz, 2017	Case series	IV	27	Thyrochondroplasty with (n = 15) or without (n = 12) cricoid approximation	—	—	—	1 case of false vocal fold hematoma (minor), 5 cases of scar erythema	—	2.71 mo
Lundgren, 2017	Case series (nonconsecutive)	IV	6	Zygomatic osteotomy (n = 6)	—	—	3D scan	—	—	11–17 mo
Meijer, 2017	Case series	IV	101	Mandibular angle reduction (n = 74), genioplasty (n = 53), forehead cranioplasty (n = 24), zygoma sandwich osteotomy (n = 20)	—	24/30 satisfied	—	5 complications, not specified	—	—
Balaji, 2016	Case series (nonconsecutive)	IV	7	Operations not specified	—	All satisfied	—	—	—	—
Bellinga, 2016	Case series (consecutive)	IV	200	Forehead contour and rhinoplasty with or without lip lift	—	26% exceptional, 46% much better, 22% a little better, 4% same, 2% worse	Nose Feminization Scale	Present, not specified; "most" paresthesias at nasal tip resolving in 3 mo	8/200 (infection, unmet expectations)	32 mo

(*Continued*)

Table 1. ***Continued***

First Author and Year	Study Type	Evidence Level	No. of Patients	Procedures Performed	Observer-Graded Appearance	Patient-Reported Satisfaction	Outcome Instrument	Complications	Revision Operations	Follow-Up (range or mean)
Capitán, 2016	Case series (nonconsecutive)	IV	65	Forehead contour, hair transplant, and other unspecified concurrent procedures	—	—	—	"Most" anterior coronal approach patients (n = 58) report scalp paresthesias, resolving 3 mo out	No revisions	26 mo
Raffani, 2016	Case series (consecutive)	IV	33	Mandible reshaping (n = 33), forehead contour (n = 31), tracheal shave (n = 26), jaw orthognathic (n = 6), revision rhinoplasty (n = 28), primary rhinoplasty (n = 5), neck liposuction (n = 7), fat graft (lip and zygoma, n = 33), submuscular aponeurotic plication (n = 4)	29/33 very much improved; 4/33 significantly improved	20/33 completely satisfied; 11/33 very much; 2/33 moderately	FFS Outcome Instrument, evaluation by 2 noninvolved surgeons	—	—	24 mo
Capitán, 2014	Case series (consecutive)	IV	172	Forehead contour (n = 172), genioplasty (n = 99), mandibuloplasty (n = 63), mandibular angle osteotomy (n = 42)	—	65% completely satisfied, 26% very satisfied, 8% satisfied	—	—	—	28 mo
Hoenig, 2011	Case series	IV	21	Forehead contour	Good–excellent (n = 15), satisfactory (n = 2)	"Overall satisfaction was very high"	2 residents graded on 5-point scale	—	—	18 mo
Spiegel, 2011	Case series (consecutive)	IV	168	Forehead contour, genioplasty, mandibuloplasty, hairline advancement, brow lift, rhinoplasty, neck liposuction	82% of postoperative forehead, 87% of postoperative midface, and 85% of postoperative lower faces were judged as women	—	100 random observers asked to grade femininity of isolated facial regions	3: 2 in patients with previous cranioplasties; all in early operations before bone paste was use to fill gaps.	2 of the 3 complication patients pursued revision with author; the other pursued revision elsewhere	2–53 mo
Ainsworth, 2010	Survey study	IV	247 total (100 with FFS, 147 controls)	Operations not specified	—	Increased QOL associated with FFS	FFS Outcome Instrument, SF36v2	—	—	—

(*Continued*)

Table 1. ***Continued***

First Author and Year	Study Type	Evidence Level	No. of Patients	Procedures Performed	Observer-Graded Appearance	Patient-Reported Satisfaction	Outcome Instrument	Complications	Revision Operations	Follow-Up (range or mean)
Shams, 2009	Case series	IV	10	Forehead contour, mandibuloplasty, zygoma osteotomies, genioplasty, rhinoplasty, hairline advancement, orbital contouring, tracheal shave	—	All satisfied	—	—	—	—
Becking, 2007	Case series (nonconsecutive)	IV	35	Mandibular angle reduction ($n = 23$), chin reduction ($n = 14$), zygoma osteotomies ($n = 3$), bimaxillary osteotomies ($n = 3$), forehead contour ($n = 2$)	—	All satisfied	—	—	—	—
Noureai, 2007	Case series	IV	12	Rhinoplasty	—	5 claimed the nose was the most important feature in defining femininity; 11/12 satisfied	Nasal measurements, 5-point scale for patients	—	4 nasal valve reconstructions	12 mo
Hage, 1997	Case series	IV	22	Rhinoplasty	—	All satisfied and convinced appearance became more feminine	—	1 cartilaginous supratip swelling	4 requested revision	28 mo
Becking, 1996	Case series	IV	16	Mandibular angle reduction ($n = 10$), genioplasty ($n = 7$), bimaxillary osteotomy ($n = 2$), and zygoma accentuation ($n = 1$) and zygoma sandwich osteotomies ($n = 1$)	—	All patients felt they appeared more feminine	—	—	—	—
Osterhout, 1987	Case series	IV	26 (5 trans patients)	Forehead contour	—	All satisfied	—	—	—	3–108 mo

FFS, facial feminization surgery; CT, computed tomographic; TMJ, temporomandibular joint; TCS, Transgender Congruence Scale; BIS, Body Image Scale; HAD, Hospital Anxiety and Depression Scale; SDS, Sheehan Disability Scale; QOL, quality of life; SF36v2, 36-Item Short-Form Health Survey version 2.

Table 2. Facial Feminization Surgery Outcome Score Changes*

Study	Design	No. of Participants	Assessment Instrument	Outcome Score
Ainsworth and Spiegel, 2010[3]	Cross-sectional	75 with previous FFS score; 172 without previous FFS score	FFS Outcome score	Previous FFS score: 76 ± 17.7 No FFS score: 44.3 ± 15.7
Morrison et al., 2019[6]	Prospective	66	FFS Outcome score	Preoperative: 48.0 ± 12.3 Short-term postoperative: 74.6 ± 14.6 Long-term postoperative: 76.5 ± 14.6

FFS, Facial Feminization Surgery.
*Outcome scores are reported for retrospective and prospective studies for facial feminization surgery using the same instrument.

MENTAL HEALTH CONSIDERATIONS

The World Professional Association for Transgender Health does not require mental health clearance for facial gender surgery as it does for various breast and genital procedures.[25] Surgeons and insurance companies now covering facial gender surgery do, however, frequently require clearance and a letter of surgical necessity from the mental health provider.

Patients presenting for facial gender surgery may or may not have had previous interventions. It is not uncommon for patients to state that facial gender surgery is the first step in their transition process and may still present in a manner congruent with their sex assigned at birth. For patients with no past assessment, thorough evaluations are standard and touch on many aspects of the person's life, such as family; development; and social, medical, and psychiatric histories. A mental status evaluation is also performed. In addition to establishing diagnosis and eligibility for such operations, a main role for the mental health evaluator is to determine whether there are any psychiatric or psychosocial issues that could complicate the patient's ability to make an informed decision. In such an event, the appropriate response may be to delay the surgery until the patient is stabilized. If diagnosis, eligibility, and psychiatric stability are established, the provider should create a letter of surgical necessity and readiness that spells out the need for the procedure.

Another key role for the mental health provider comes postoperatively. Many individuals report significant mood changes following surgery. This phenomenon is most likely the result of a combination of anesthesia, medication, pain, and dependence on others and a possible letdown response following a much-anticipated procedure. Although no articles specifically address postoperative facial gender surgery patients, articles analyzing postoperative adjustment with general facial operations and transgender genital operations show that this complication is not rare.[26–28] Anecdotal experiences of those working extensively with transgender patients are replete with cases of postoperative depression lasting days to weeks. It is imperative that a mental health provider be available to treat individuals who postoperatively display negative mood states: postoperative adjustment must be broadly addressed, encompassing not only physical recovery but psychological recovery as well.[29–31]

MEDICAL NECESSITY AND INSURANCE COVERAGE

Arguments in Favor of Medical Necessity

A core role of the World Professional Association for Transgender Health is their consensus statement on the best practices in care for transgender and gender-nonconforming individuals, also known as the *Standards of Care*. In this document, the existing literature, community input, and expert opinions are aggregated and made available to the public. The next version (*Standards of Care Version 8*) is expected to be released in 2022. The document outlines requirements medical necessity and is often used as the reference for government and third-party insurance coverage and requirements. The current wording indicates that genital surgery and chest masculinization are medically necessary, whereas facial gender surgery is lumped under "various procedures" and medical necessity is not clearly determined.[29,30]

More importantly, no criteria were defined to assist a provider in establishing the individual need and no involvement of a mental health professional was required. We believe it is time to define both criteria and medical necessity. This topic was therefore included at the inaugural International Facial Gender Symposium. The group consensus was supportive of placing mental health evaluation requirements in World Professional Association for Transgender Health *Standards of Care Version 8* on par with other core procedures.

"Medical necessity" is a frequently used term but may be difficult to define, especially in plastic surgery.[32] In 1999 a research team at Stanford University established criteria to define medical necessity.[33] If not specifically excluded from an insurance plan, the determination of medical necessity is made across five key categories (Fig. 2).

Multiple conceptual frameworks for procedural medical necessity have arisen. For example, a "mental-health-based approach" would consider as medically necessary whichever procedures yield the greatest improvement in the patient's self-image and feelings of dysphoria (e.g., twins might have different sets of medically necessary procedures). In practical terms, however, most recognize the need for more clarity. Our preferred approach is to define the medical necessity of procedures that treat features affected by exposure to testosterone during puberty (i.e., the sexually dimorphic features of the face). This has several advantages including (1) addressing a defined set of specific procedures on a conceptually rational basis (treatment of hormone effects), and (2) encompassing the core procedures that have the best data and most patients seek (i.e., forehead, nose, jaw, and tracheal reduction).

Perhaps the most challenging area in which to define a distinction between aesthetic and reconstructive is tightening procedures (e.g., neck lift). It is clear that bony reduction procedures in some patients (especially those older than 40 years) fail to result in equivalent contracture of the soft-tissue envelope. The result is not only unaesthetic, but more importantly the feminized facial skeleton often cannot be seen—negating the possibility of the surgery having the desired effect on patient self-image or treatment by others. For this reason, secondary tightening procedures to address iatrogenic sequelae of primary feminizing procedures may be considered reconstructive (as face-lift after facial paralysis may also be), whereas a procedure for the purpose of addressing aging—even with a technique that produces a more feminine but younger face—would be aesthetic. Representation of these procedures in existing cohorts is limited. Creation of evidence-based criteria for when the result of a primary procedure may warrant soft-tissue revision is a high priority.

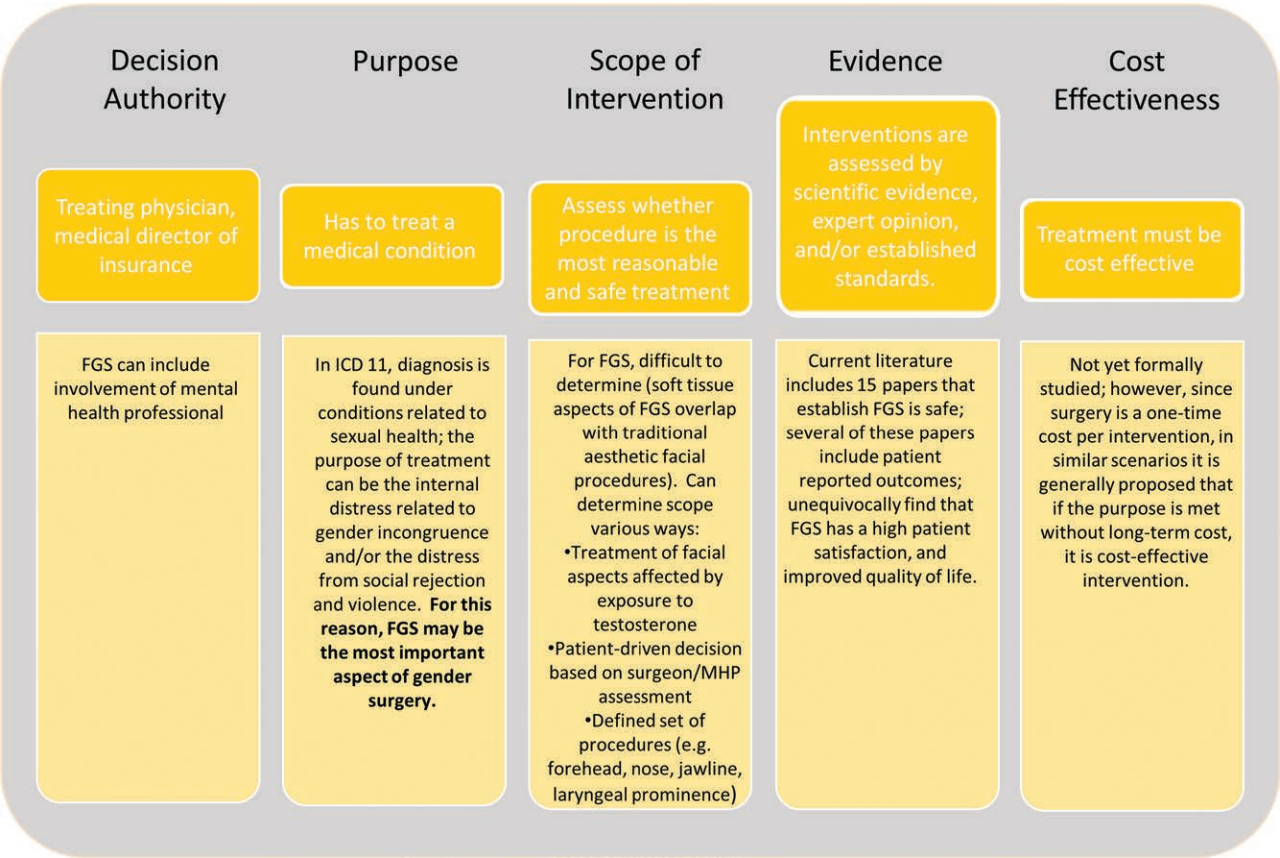

Fig. 2. Medical necessity and facial gender surgery. Medical necessity as defined by a team at Stanford University in 1999. Impact of facial gender surgery (*FGS*) is illustrated. *ICD 11, International Classification of Diseases, Eleventh Revision*.

CPT CODING

Appropriate CPT codes for facial gender surgery have not been defined by the American Society of Plastic Surgeons, presenting challenges for insurance coverage.[34] Based on the consensus opinion of the International Facial Gender Symposium, listed CPT codes are appropriate to submit for preauthorization/reimbursement for facial gender procedures. Table 3 lists all codes relevant to facial gender surgery; some may be considered cosmetic; this will be determined by each payor. However, core facial gender surgery procedures are by consensus considered as not being cosmetic (see points 1 and 2 under Conclusions).

Preauthorization should be supported by comprehensive clinical evaluation and diagnostic studies, including computed tomography. In certain cases, the closest CPT codes by description represent a substantial mismatch between work and relative value unit valuation. In these cases, the most appropriate code may be the unlisted code (21299), with submission of a comparator code and documentation supporting similarities. For example, bilateral inferior border ostectomy from angle to symphysis from an intraoral approach is time-consuming and challenging; thus, 21299 with comparator code 21193 is appropriate. Given the complexity of bony osteotomies necessary to achieve a gender-congruent facial appearance, virtual surgical planning is often indicated.[35]

Table 3. CPT Codes for Facial Gender Surgery by Facial Region

Facial Region	CPT Code(s)	CPT Code Description
Upper face	14020-1, 14301-2	Adjacent tissue transfer, forehead (galeal advancement)
	21137	Forehead contouring (reduction only)
	21139	Forehead, anterior frontal sinus wall setback
	21208	Augmentation osteoplasty
	21209	Reduction osteoplasty (orbital reshaping)
	67900	Repair of brow ptosis (post–forehead reduction ptosis)
	21299	Unlisted craniofacial and maxillofacial procedure
Midface	14060-1	Adjacent tissue transfer, lip
	15730	Midface flap (malar resuspension)
	15773-4	Autologous fat grafting
	21141-7	Le Fort I midface reconstruction
	21188	Reconstruction midface with osteotomies, non-Le Fort (e.g., zygomatic osteotomies)
	21208	Augmentation osteoplasty
	21209	Reduction osteoplasty
	21270	Malar augmentation (alloplastic)
	30410-50	Rhinoplasty (primary or secondary)
	30465	Vestibular stenosis repair
	30520	Septoplasty
	15825; 15828-9	Rhytidectomy; platysmal tightening (secondary, after jaw reduction)*
Lower face	15773-4	Fat grafting
	21025	Excision of mandibular bone
	21120	Augmentation genioplasty
	21121-3	Sliding genioplasty
	21193-6	Mandibular rami reconstruction (e.g., intraoral border osteotomy)
	21125-7	Augmentation, mandible (prosthetic or graft)
	21209	Reduction osteoplasty
	31750	Cervical tracheoplasty (thyroid cartilage reduction)
	15876	Cervical liposuction* (secondary, after jaw reduction)
	21299	Unlisted craniofacial and maxillofacial procedure*
Other	0055T	Preoperative computed tomography–based virtual planning
	20985	Intraoperative surgical computer guidance or navigation

*No relative value units value assigned.

SURGICAL TECHNIQUES

Forehead

Structural modification of the forehead is undoubtedly the most extensively developed procedure in the literature related to facial gender surgery. Feminization of the forehead aims to modify the primary markers of gender in that area: frontal bossing and frontal eminences, supraorbital rims and ridges, the frontonasal angle, and temporal ridges. As a result of modifying the craniofacial bone structure, the soft tissues located in this area undergo a readaptation process that allows the face to appear more feminine.[36]

Most authors advocate for sinus reconstruction as the primary surgical technique.[13,14,37] However, a small number of authors opt for isolated bone shaving techniques or the addition of alloplastic material.[38,39] From review of the literature, it is clear that the frontal sinus is a significant factor that influences surgical technique and considerably limits results. This limitation is particularly apparent if the reconstructive approach is not appropriate or if bone shaving is the sole technique used in patients with voluminous or thin-walled sinuses.

At this time, there is no evidence of a gold standard reconstructive method. Regardless of the technique used, it is essential to maintain recognizable anatomical parameters, guarantee sinus function, and preserve the integrity of the frontonaso-orbital complex.

Future Directions

Standardization of the reconstructive process in forehead surgery needs to include the creation of multicenter working groups using a significant sample size to analyze basic factors: anatomical type, sinus variability, descriptions of osteotomies, orbital reshaping, analysis of anterior wall fixation methods and the materials used, and long-term follow-up of sinus behavior and complications.

Lower Jaw

Jaw and chin reshaping techniques constitute another pillar of facial feminization structural surgery. Despite the high demand for this treatment, the literature reviewed does not specifically include key factors related to diagnosis, clinical indication, or techniques. Most authors agree that the anatomical differences between the masculinized and feminized jaw are obvious.[40,41] Moreover, there is also near unanimity that feminization procedures carried out on the jaw and chin must be approached intraorally and that the objective of all the different surgical techniques is to modify jaw format and decrease bone volume.[42,43] Beyond this, several alternative techniques come into play that include bone shaving, osteotomies, and ostectomies at different key points for gender identification, such as the angles, body, and chin. An important adjunct is the removal of facial hair by laser or electrolysis. Common sense suggests that jaw surgery in the absence of beard removal will not allow for creation of a feminine jaw appearance.

Future Directions

Standardization of chin and jaw reshaping requires the analysis of anatomical classifications of different male jaw patterns, the use of planning and diagnostic software with customized surgical guides, and screening of complications. Prospective studies are necessary to evaluate the behavior of soft tissues across various ages after structural bone surgery. With a more general understanding of this behavior, it will be possible to establish with more certainty whether soft tissues will need compensatory treatment for postostectomy laxity.

Nose

The size, shape, age, and ethnicity of the nose all must be evaluated when planning a rhinoplasty in the context of facial gender surgery to achieve a threefold objective: (1) feminization of the nose; (2) harmonization with regard to the other modified structures (primarily the forehead and maxillomandibular complex); and (3) achieving an aesthetic result.[11]

Rhinoplasty is a highly individualized procedure that requires a complete evaluation of the bone and cartilaginous structures that form the nose. Although patients vary widely, the following represent the most common maneuvers: feminization of the profile (dorsal reduction and narrowing), caudally shortening and deprojecting the nasal tip, and creation of a smaller tip with a supratip break.

Feminizing rhinoplasty is a reductive procedure that may impair the nasal airway. Many transgender patients have also been the victims of violence and may have posttraumatic nasal deformities. Septoplasty has a role to address septal deviations and offset the effects of substantial reduction of the nasal profile and tip projection. Liberal use of spreader grafts and flaps to maintain the internal nasal valve and prevent the inverted-V deformity is suggested. Assessment of valve competence, septal status, and other functional considerations are an equally important part of gender rhinoplasty evaluation and planning.

Future Directions

Rhinoplasty is the most developed of these three areas in certain aspects, as many tools developed for traditional rhinoplasty are relevant. High priority areas for research include more in-depth linkage of the changes from rhinoplasty to the resulting effects on patient quality of life. Currently, it is generally presumed that the most successful improvement to mental health is obtained by creating what is, in the surgeon's judgment, the most appropriately feminine nose for the face. However, there may be a role for either structured patient input or objective evaluation systems. Studies of nasal functional outcomes with feminizing rhinoplasty are also high priority areas for research. Lastly, across all facial gender surgery procedures, it is important to define ideal time points for facial gender surgery outcome measurement in all of these studies, especially rhinoplasty.

CONCLUSIONS

This publication represents the first-ever consensus statement from an international group including surgeons, psychologists, and researchers focused on the area of facial gender surgery, with an aggregated experience that spans thousands of facial gender surgery patients. Our current assessment is as follows:

1. The evidence demonstrates that core facial gender operations are not cosmetic, are medically necessary, and should be covered by insurance like other gender operations. The *Standards of Care Version 8* should reflect the similarities between facial and other gender operations. In particular, the following procedures address the most common concerns and are shown to (a) make the face more feminine to observers and may decrease misgendering; (b) improve patient-reported facial perception and quality of life; and (c) cannot be dismissed as "cosmetic," as they arise solely from either the effect of testosterone on facial development or iatrogenic sequelae.

    a. Forehead contouring/frontal sinus setback, rhinoseptoplasty, mandibular angle and body contouring, genioplasty, thyroid chondroplasty.
    b. Secondary procedures to correct iatrogenic results of these procedures: neck tightening and browpexy caused by ptosis after bony skeleton volume reduction.
    c. Facial hair removal (laser/electrolysis).

2. Additional evidence is necessary to demonstrate the effects of certain other facial gender surgery procedures. These procedures may have mixed feminizing-aesthetic components and present data are limited because current studies generally include the "primary procedures" above.

    a. Lip lift, fat grafting, malar augmentation, midface lift, face lift, blepharoplasty.

3. Facial masculinization should be evaluated on a case-by-case basis and treated as medically necessary when clinical evidence and mental health evaluations support this.

There are limited data on facial masculinization, and most surgeons have received few requests. The effect of exogenous testosterone has profound effects on soft tissues and facial hair, which may be enough to allow individuals to be socially recognized as male. However, in certain cases, these changes are inadequate, and these procedures, as the inverse of feminizing procedures, can have a psychological impact similar to that with facial feminization surgery.[44] Assessment of medical necessity should be done with a mental health expert and based on documentation of psychological issues and physical features that surgery can reasonably be expected to fix. Additional research should be performed to identify which transmale patients benefit from facial gender surgery.

4. Additional CPT codes should be developed to cover facial gender surgery procedures, with best-existing alternatives used in the interim. Other than frontal sinus setback, few other procedures have well-matched procedure codes. The codes in section IV are felt to represent the best match among existing codes based on relevance and procedural difficulty and should be accepted by insurance companies covering these procedures.
5. Consideration should be given to offering facial gender surgery procedures within the context of a multidisciplinary team or transgender medicine program. Across medicine, the importance of multidisciplinary patient care is increasingly recognized. Although it is not necessary that all facial gender surgery surgeons be part of a program, having a practice setting that cares for a meaningful volume of transgender patients in a year and direct access to complementary disciplines such as mental health are important adjuncts in ensuring comprehensive, holistic care.
6. Standards should be developed to define adequate training to perform facial gender surgery. Although learning curves are inevitable, a growing number of secondary complications are being seen from surgeons with no training of any kind in facial gender surgery. World Professional Association for Transgender Health (in *Standards of Care Version 8*) and other surgical societies should take the lead in protecting patients by formalizing what is considered appropriate preparation for performing facial gender surgery, including (a) appropriate specialties and board-certification status, and (b) appropriate exposure to and training in facial gender surgery techniques.
7. Research should be performed to provide additional granularity on both patient and procedural subsets, with better validation of patient-reported metrics, objective standards for outcomes evaluation, and definition of optimal time points for

measurement. Current data prove that, in cohorts where most patients received "full face" treatment, substantial improvements result. Larger, multicenter, prospective studies with sufficient sample size are needed to advance the science further and identify (a) how to predict which patients benefit the most, and (b) identify the individual impact of each procedural type within facial gender surgery.

Devin Coon, M.D., M.S.E.
Department of Plastic Surgery
Johns Hopkins Hospital
601 North Caroline Street, JHOC 8161
Baltimore, Md. 21287

REFERENCES

1. Meerwijk EL, Sevelius JM. Transgender population size in the United States: A meta-regression of population-based probability samples. *Am J Public Health* 2017;107:e1–e8.
2. Capitán L, Simon D, Berli JU, et al. Facial gender confirmation surgery: A new nomenclature. *Plast Reconstr Surg.* 2017;140:766–767.
3. Ainsworth TA, Spiegel JH. Quality of life of individuals with and without facial feminization surgery or gender reassignment surgery. *Qual Life Res.* 2010;19:1019–1024.
4. Ousterhout DK. Feminization of the forehead: Contour changing to improve female aesthetics. *Plast Reconstr Surg.* 1987;79:701–713.
5. Lundgren TK, Farnebo F. Midface osteotomies for feminization of the facial skeleton. *Plast Reconstr Surg Glob Open* 2017;5:e1210.
6. Becking AG, Tuinzing DB, Hage JJ, Gooren LJ. Transgender feminization of the facial skeleton. *Clin Plast Surg.* 2007;34:557–564.
7. Nouraei SAR, Randhawa P, Andrews PJ, Saleh HA. The role of nasal feminization rhinoplasty in male-to-female gender reassignment. *Arch Facial Plast Surg.* 2007;9:318–320.
8. Hage JJ, Vossen M, Becking AG. Rhinoplasty as part of gender-confirming surgery in male transsexuals: Basic considerations and clinical experience. *Ann Plast Surg.* 1997;39:266–271.
9. Becking AG, Tuinzing DB, Hage JJ, Gooren LJG. Facial corrections in male to female transsexuals: A preliminary report on 16 patients. *J Oral Maxillofac Surg.* 1996;54:413–418; discussion 419.
10. Balaji SM. Facial feminization: Surgical modification for Indian, European and African faces. *Ann Maxillofac Surg.* 2016;6:210–213.
11. Bellinga RJ, Capitán L, Simon D, Tenório T. Technical and clinical considerations for facial feminization surgery with rhinoplasty and related procedures. *JAMA Facial Plast Surg.* 2017;19:175–181.
12. Capitán L, Simon D, Meyer T, et al. Facial feminization surgery: Simultaneous hair transplant during forehead reconstruction. *Plast Reconstr Surg.* 2017;139:573–584.
13. Raffaini M, Magri AS, Agostini T. Full facial feminization surgery: Patient satisfaction assessment based on 180 procedures involving 33 consecutive patients. *Plast Reconstr Surg.* 2016;137:438–448.
14. Capitán L, Simon D, Kaye K, Tenório T. Facial feminization surgery: The forehead. Surgical techniques and analysis of results. *Plast Reconstr Surg.* 2014;134:606–619.
15. Hoenig JF. Frontal bone remodeling for gender reassignment of the male forehead: A gender-reassignment surgery. *Aesthetic Plast Surg.* 2011;35:1043–1049.
16. Spiegel JH. Facial determinants of female gender and feminizing forehead cranioplasty. *Laryngoscope* 2011;121:250–261.
17. Shams MG, Motamedi MH. Case report: Feminizing the male face. *Eplasty* 2009;9:e2.
18. Gupta N, Wulu J, Spiegel JH. Safety of combined facial plastic procedures affecting multiple planes in a single setting in facial feminization for transgender patients. *Aesthetic Plast Surg.* 2019;43:993–999.
19. Isung J, Möllermark C, Farnebo F, Lundgren K. Craniofacial reconstructive surgery improves appearance congruence in male-to-female transsexual patients. *Arch Sex Behav.* 2017;46:1573–1576.
20. Lipschitz N, Wolf M, Amir O, Sagiv D, Primov-Fever A. Thyroid chondroplasty: Smoothing the thyroid cartilage. A retrospective study of thyroid chondroplasty for feminine neck appearance. *Int J Transgenderism* 2017;18:389–394.
21. Meijer B, Moghimi M, Forouzanfar T. Facial feminisation surgery: 18 years of experience in Amsterdam. *Int J Oral Maxillofac Surg.* 2017;46:164.
22. Mommaerts MY, Voisin C, Joshi Otero J, Loomans NAJ. Mandibular feminization osteotomy: Preliminary results. *Int J Oral Maxillofac Surg.* 2019;48:597–600.
23. Alsarraf R. Outcomes research in facial plastic surgery: A review and new directions. *Aesthetic Plast Surg.* 2000;24:192–197.
24. Morrison SD, Capitán-Cañadas F, Sánchez-García A., et al. Prospective quality-of-life outcomes after facial feminization surgery: An international multicenter study. *Plast Reconstr Surg.* 2020;145:1499–1509.
25. Esmonde N, Najafian A, Penkin A, Berli JU. The role of facial gender confirmation surgery in the treatment of gender dysphoria. *J Craniofac Surg.* 2019;30:1387–1392.
26. Vaidya TS, Mori S, Dusza SW, Rossi AM, Nehal KS, Lee EH. Appearance-related psychosocial distress following facial skin cancer surgery using the FACE-Q Skin Cancer. *Arch Dermatol Res.* 2019;311:691–696.
27. LeBreton M, Courtois F, Journel NM, et al. Genital sensory detection thresholds and patient satisfaction with vaginoplasty in male-to-female transgender women. *J Sex Med.* 2017;14:274–281.
28. Líndal E. Post-operative depression and coronary bypass surgery. *Disabil Rehabil.* 1990;12:70–74.
29. Berli JU, Capitán L, Simon D, Bluebond-Langner R, Plemons E, Morrison SD. Facial gender confirmation surgery: Review of the literature and recommendations for Version 8 of the WPATH Standards of Care. *Int J Transgenderism* 2017;18:264–270.
30. Coleman E, Bockting W, Botzer M, et al. Standards of Care for the Health of Transsexual, Transgender, and Gender-Nonconforming People, Version 7. *Int J Transgenderism* 2012;13:165–232.
31. Capitán L, Gutiérrez-Santamaría J, Simon D, et al. Facial gender confirmation surgery: A protocol for diagnosis, surgical planning, and postoperative management. *Plast Reconstr Surg* 2020;145:818e—828e.
32. Kerrigan CL, Collins ED, Kim HM, et al. Reduction mammaplasty: Defining medical necessity. *Med Decis Making* 2002;22:208–217.
33. Singer S, Bergthold L, Vorhaus C, et al. Decreasing variation in medical necessity decision making. *Health Care (Don Mills)* 1999;98.

34. Weiss P, Schechter L. Coding for sex-reassignment surgery is evolving. *Plast Surg News.* 2015:14.
35. Gray R, Nguyen K, Lee J, et al. Osseous transformation with facial feminization surgery. *Plast Reconstr Surg.* 2019;144:1159–1168.
36. Capitán L, Simon D, Capitán-Cañadas F. Facial feminization surgery and facial gender confirmation surgery. In: Ferrando C, ed. *Comprehensive Care of the Transgender Patient.* New York: Elsevier; 2019:55–73.
37. Bachelet JT, Souchere B, Mojallal A, Gleizal A, Boucher F. Facial feminization surgery: Upper third (in French). *Ann Chir Plast Esthet.* 2016;61:877–881.
38. Altman K. Forehead reduction and orbital contouring in facial feminisation surgery for transgender females. *Br J Oral Maxillofac Surg.* 2018;56:192–197.
39. Villepelet A, Jafari A, Baujat B. Fronto-orbital feminization technique. A surgical strategy using fronto-orbital burring with or without eggshell technique to optimize the risk/benefit ratio. *Eur Ann Otorhinolaryngol Head Neck Dis.* 2018;135:353–356.
40. Morrison SD, Satterwhite T. Lower jaw recontouring in facial gender-affirming surgery. *Facial Plast Surg Clin North Am.* 2019;27:233–242.
41. Deschamps-Braly J. Feminization of the chin: Genioplasty using osteotomies. *Facial Plast Surg Clin North Am.* 2019;27:243–250.
42. Jin H. Misconceptions about mandible reduction procedures. *Aesthetic Plast Surg.* 2005;29:317–324.
43. Ellis E, Zide MF. Mandibular vestibular approach. In: *Surgical Approaches to the Facial Skeleton.* 3rd ed. Philadelphia: Lippincott Williams & Wilkins; 2018:137–150.
44. Ousterhout DK. Dr. Paul Tessier and facial skeletal masculinization. *Ann Plast Surg.* 2011;67:S10–S15.