

available at www.sciencedirect.com
journal homepage: www.europeanurology.com



European Association of Urology



Surgery in Motion

Outcomes of Gender Affirming Peritoneal Flap Vaginoplasty Using the Da Vinci Single Port Versus Xi Robotic Systems

Geolani W. Dy^{a,†}, Min Suk Jun^{b,†}, Gaines Blasdel^b, Rachel Bluebond-Langner^c, Lee C. Zhao^{b,*}

^a Department of Urology, Oregon Health & Science University, Portland, OR, USA; ^b Department of Urology, New York University Langone Medical Center, New York, NY, USA; ^c Hansjörg Wyss Department of Plastic Surgery, New York University Langone Medical Center, New York, NY, USA

Article info

Article history:

Accepted June 17, 2020

Associate Editor:

Alexandre Mottrie

Keywords:

Transgender
Vaginoplasty
Robotic surgery
Single port

Please visit

www.europeanurology.com and
www.urosourc.com to view the
accompanying video.

Abstract

Background: Robotic-assisted peritoneal flap gender-affirming vaginoplasty (RPGAV) with the da Vinci Xi system has been reported to be a safe alternative to traditional penile inversion vaginoplasty. Utilizing the Single Port (SP) robot system, our surgical approach has evolved.

Objective: To describe a step-by-step technique for RPGAV using the SP robot and to compare outcomes between Xi and SP systems.

Design, setting, and participants: A total of 145 transgender women underwent RPGAV between September 2017 and December 2019. We retrospectively reviewed data for patients with a minimum 6 mo of follow-up.

Surgical procedure: Peritoneal flaps are harvested from the posterior bladder and para-rectal fossa. The vaginal space is dissected transabdominally. Inverted penile flap with or without scrotal graft is sutured to the peritoneal flaps, which form the neovaginal apex.

Measurements: Demographics, perioperative data, and clinical outcomes were evaluated.

Results and limitations: A total of 100 (Xi = 47; SP = 53) patients had a minimum 6 mo of follow-up. The mean age was 36.2 (range 16.1–71.4) yr. Average procedure times were 4.2 and 3.7 h in Xi and SP cohorts, respectively ($p < 0.001$). At the mean follow-up of 11.9 (range 6.0–25.4) mo, vaginal depth and width were 13.6 (range 9.7–14.5) and 3.7 (range 2.9–3.8) cm in the Xi group, and 14.1 (range 9.7–14.5) and 3.7 (range 3.5–3.8) cm in the SP group ($p = 0.07$ and 0.04 , respectively). Complications included transfusion (6%), rectovaginal fistula (1%), bowel obstruction (2%), pelvic abscess (1%), and vaginal stenosis (7%).

Conclusions: RPGAV using the SP robot reduces operative time by facilitating a dual-surgeon abdominal-perineal approach. There is no difference in complication rates between the two approaches.

Patient summary: We studied the outcomes of robotic peritoneal flap vaginoplasty with two robot systems. With both systems, patients had good vaginal depth and width at an average follow-up of 1 yr. Surgery time was shorter with the Single Port (SP) robot.

© 2020 European Association of Urology. Published by Elsevier B.V. All rights reserved.

[†] These authors contributed equally to this work.

* Corresponding author. Department of Urology, New York University, 11th Floor, 222 East 41st St., New York, NY 10017, USA. Tel. +1 (646) 825 6300, Fax: +1 (646) 825 6377.

E-mail address: Lee.zhao@nyulangone.org (L.C. Zhao).

www.europeanurology.com and www.urosources.com to view the accompanying video.

1. Introduction

An estimated 50% of transgender women are interested in vaginoplasty [1], and demand for gender-affirming procedures is increasing worldwide [2,3]. Penile inversion vaginoplasty (PIV) is the most commonly used technique for genital reconstruction in transgender women and nonbinary individuals desiring female genitalia [4]. The components of PIV include neovaginal cavity creation, vulvoplasty, clitoroplasty, corpora cavernosa reduction, orchiectomy, and urethroplasty.

Robotic-assisted peritoneal flap gender-affirming vaginoplasty (RPGAV) using a modified Davydov technique with the da Vinci Xi robot (Intuitive Surgical Inc., Sunnyvale, CA, USA) has been described by our institution as an alternative to traditional PIV [5]. The main differences between RPGAV and traditional PIV are the following: (1) antegrade, transabdominal dissection of the neovaginal cavity, and (2) mobilization of peritoneal flaps to create the neovaginal apex as an extension of the inverted penoscrotal skin in the rectovesical pouch, which is then (3) excluded from the peritoneal cavity. RPGAV offers the potential for full vaginal depth of 12–14 cm in the setting of limited genital skin, while minimizing donor-site complications of extragenital skin grafts or intestinal segments.

Following the release of the da Vinci Single Port (SP) robot in 2018, we adapted our multiarm RPGAV technique for the SP system with several potential benefits. We herein provide a comparison of the surgical technique and patient outcomes between Xi and SP systems and describe a step-by-step technique for SP RPGAV.

2. Patients and methods

2.1. Patients

From September 2017 to December 2019, 145 transgender women underwent RPGAV. The Xi system was used in 55 (September 2017 to November 2018) and the SP system in 90 (October 2018 to December 2019). Early outcomes of the first 41 patients undergoing RPGAV using the Xi system have been described previously [5]; their outcomes are included in this analysis, which is updated to reflect longer-term follow-up. Patients with <6 mo of follow-up were excluded.

Patient demographics, comorbidities, and preoperative characteristics are compared between Xi and SP patient cohorts using *t*-tests and chi-square analysis. Outcome variables include: perioperative details (operative time and blood loss), complications (intra- and postoperative), and postoperative neovaginal dimensions (depth and width determined by patient-reported maximum dilator depth and size at the most recent follow-up). Depth is measured from the urethral meatus.

We hypothesize that surgical time is shorter in RPGAV using the SP system, and that there is no difference in complications or vaginal depth between the two systems.

2.2. Technique

All cases were performed jointly by two surgeons (L.C.Z. [reconstructive urology] and R.B.L. [plastic surgery]). Patients are positioned in lithotomy with yellow fins with sequential compression devices. Arms are tucked to the side. Subcutaneous heparin and piperacillin-tazobactam prophylaxis are administered. Chlorhexidine is applied from the xiphoid to the proximal thighs. An O'Connor drape is used to facilitate sterile rectal access during vaginal canal dissection. A Foley catheter is placed.

Our operative steps for scrotal full-thickness skin graft harvest, penile disassembly, urethroplasty, clitoroplasty, orchiectomy, vulvoplasty, and robotic-assisted canal dissection and peritoneal flap mobilization using the Xi system have been described previously [5].

We make a semicircular incision supraumbilically and a 2.7 cm vertical fasciotomy. The peritoneum is incised sharply. The SP trocar is placed under direct vision. The patient is placed in 30° Trendelenburg. The abdomen is insufflated to 15 mmHg for 5 mm assistant port placement under direct vision two fingerbreadths above the anterior superior iliac spine. The robot is side docked.

Our preferred instruments are bipolar Maryland forceps, monopolar scissors, and needle driver. Sigmoid adhesiolysis is performed to fully expose the rectovesical space. A horizontal peritoneal incision is made overlying the seminal vesicles. This incision is widened laterally beneath the vas deferens bilaterally. Dissection is advanced posterior to the seminal vesicles. Denonvillier's fascia is incised to develop a space between the prostate and rectum. An EEA sizer or digital rectal guidance may be used to visualize the correct plane to avoid rectal injury. Concurrently, a full-thickness scrotal skin graft is harvested, tubularized around a 38-mm (#4, orange) Soul Source dilator (North Hollywood, CA, USA), and sewn onto the penile skin tube. In some cases, the penile skin tube is sufficiently long and skin graft is unnecessary. The levator ani and pelvic side-wall musculature are incised to widen the canal until it accommodates the 38 mm dilator easily. Concurrently, the perineal dissection is advanced beneath the bulbar urethra and through the perineal body to the level of the perineal membrane. The robotic dissection is continued toward the perineum until the transabdominal and perineal dissection spaces are joined. If bleeding from the prostatic pedicles is encountered, suture ligation is preferred over cautery to avoid rectal injury. The pneumoperitoneum will eject blood toward the perineal surgeon. For this reason, we use an orthopedic helmet for protection.

Attention is then turned to raising a 12 cm × 12 cm anterior peritoneal flap from the posterior aspect of the bladder. The medial umbilical ligaments serve as the lateral borders. The posterior peritoneal flaps are raised adjacent to the rectum, with the ureters serving as the lateral borders and the sacral promontory as the superior border.

The penoscrotal tube is inverted and passed into the vaginal cavity. The posterior peritoneal flap is sutured to the inferior ventral penoscrotal skin, and the anterior peritoneal

flap is sutured to the dorsal aspect using a barbed 3-0 absorbable suture, creating a circumferential anastomosis. If the peritoneal flaps have limited distal reach, we lengthen the penoscrotal tube to ensure a tension-free anastomosis. At the apex of the neovagina, the posterior peritoneal flaps are sutured together across the rectum, then sutured to the apex of the anterior flap. The anterior and posterior flaps are approximated in running fashion using 3-0 absorbable barbed suture to exclude the vagina from the abdominal cavity. Vaginal packing of rolled gauze soaked with mupirocin, bacitracin, and lubricant is placed prior to complete closure of the vaginal apex to ensure extension into the neovaginal apex.

The fascia is closed with running 0-Vicryl suture; 3-0 Vicryl approximates subcutaneous tissue. Subcuticular 4-0 Monocryl closes the skin. A negative pressure wound dressing is applied over the introitus. Kerlix and abdominal pads are placed over this dressing followed by compressive elastic tape.

2.3. Postoperative care

Patients are placed on bed rest for 1 d with subsequent progressive mobilization. On postoperative day 5, the dressing, vaginal packing and Foley catheter are removed, and the patient dilates with the 32 (blue, #2) or 35 mm (green, #3) dilator. Once they are able to demonstrate independent dilation and after a trial of void, they are discharged home with instructions to dilate four times daily, for 15 min each time. Over the next 6 wk, the patient gradually increases to a goal width of 38 mm (orange, #4) and depth of 14.5 cm. Antibiotics and venous thromboembolism prophylaxis are continued for the duration of the hospitalization.

Patients are seen in a multidisciplinary clinic after discharge for postoperative checks, including speculum examinations at 2, 3, 4, 6, and 12 wk; 6 mo; and then annually. Individuals who have difficulty with dilation are referred to pelvic floor physical therapy. Vaginal depth and width are recorded based on patient self-reported dilation depth (dots visible at the vaginal introitus) and dilator

diameter. After successful dilation for 3 mo, patients are allowed to have receptive vaginal intercourse. We encourage patients to have continued follow-up with their mental health providers and will contact them proactively when appropriate.

3. Results

The mean age at the time of surgery was 36.2 (range 16.1–71.4) yr. There were no differences in patient age, circumcision status, or time on hormonal therapy. There were no differences in comorbidities between the two groups except for a higher incidence of pubertal blockade in the Xi cohort, and a higher body mass index and incidences of smoking in the SP cohort (Table 1).

Average procedure times were 254 and 220 min in the Xi and SP cohorts, respectively ($p < 0.001$). Procedure time decreased over consecutive cases for both robotic platforms (Table 2 and Fig. 1). To control for the learning curve, the last 25 Xi cases were compared with the last 25 SP cases. The average procedure time was 240 min for Xi and 203 min SP ($p < 0.001$).

No complications were identified intraoperatively. Six patients (6%) required transfusions during the postoperative period for anemia (hemoglobin [Hgb] < 7 g/dl) or symptomatic anemia (Hgb < 8 g/dl). The mean length of stay was 5.1 (range 5–7) d. Thirteen patients (13%) required reoperation for any reason over the follow-up period for a variety of indications listed in Table 3. One patient developed rectovaginal fistula (1%), presenting 2 wk postoperatively. Robotic primary repair without fecal diversion 6 mo after vaginoplasty resulted in a recurrent but much smaller fistula. The patient has minimal symptoms and has been engaging in satisfactory vaginal intercourse.

Two patients were readmitted with bowel obstruction: one with a history of inflammatory bowel disease, resolving after bowel rest, and another with herniation of small bowel through a separation in the peritoneal flap closure. This patient presented 7 d postoperatively, and underwent laparoscopic reduction of the hernia and closure of the

Table 1 – Patient characteristics.

Demographic	Total	Xi system	SP system	<i>p</i> value
Number of patients (total), <i>n</i>	145	55	90	
Number of patients (>6 mo follow-up)	100	47	53	
Age (yr), mean (range)	36.2 (16.1–71.4)	34.5 (16.1–71.4)	37.7 (18.7–67.3)	0.230
BMI (kg/m ²), mean (range)	25.3 (14.6–38.1)	24.2 (14.6–35.1)	26.4 (18.3–38.1)	0.024
Smoker (current or former), <i>n</i> (%)	29 (29)	10 (21)	19 (36)	0.023
Diabetes, <i>n</i> (%)	2 (2)	1 (2)	1 (2)	0.903
Bleeding disorder, <i>n</i> (%)	0 (0)	0 (0)	0 (0)	–
HIV, <i>n</i> (%)	10 (10)	6 (13)	4 (8)	0.219
Prostate condition, <i>n</i> (%)	2 (2)	1 (2)	1 (2)	0.903
Pubertal blockade history, <i>n</i> (%)	5 (5)	4 (9)	1 (2)	0.032
Duration hormonal therapy (yr), median (range)	3.7 (1.2–38.1)	3.37 (1.5–37.7)	4.1 (1.2–38.0)	0.600
Ability to orgasm (preoperatively), <i>n</i> (%)	86 (86)	42 (89)	44 (83)	0.197
Utilized penis for penetrative intercourse (preoperatively), <i>n</i> (%)	14 (14)	3 (6)	11 (21)	0.003
Circumcised, <i>n</i> (%)	80 (82)	38 (83)	42 (81)	0.740

BMI = body mass index; HIV = human immunodeficiency virus.

Table 2 – Perioperative details.

Detail	Total	Xi system (n = 47)	SP system (n = 53)	p value
Total operative time (min), mean +/- SD	236.4 ± 39.2	254 ± 35.2	221 ± 36.1	<0.001
Length of hospital stay (d), mean (range)	5.1 (5–7)	5.1 (5–6)	5.0 (5–7)	0.620
SD = standard deviation.				

Operating time over consecutive cases

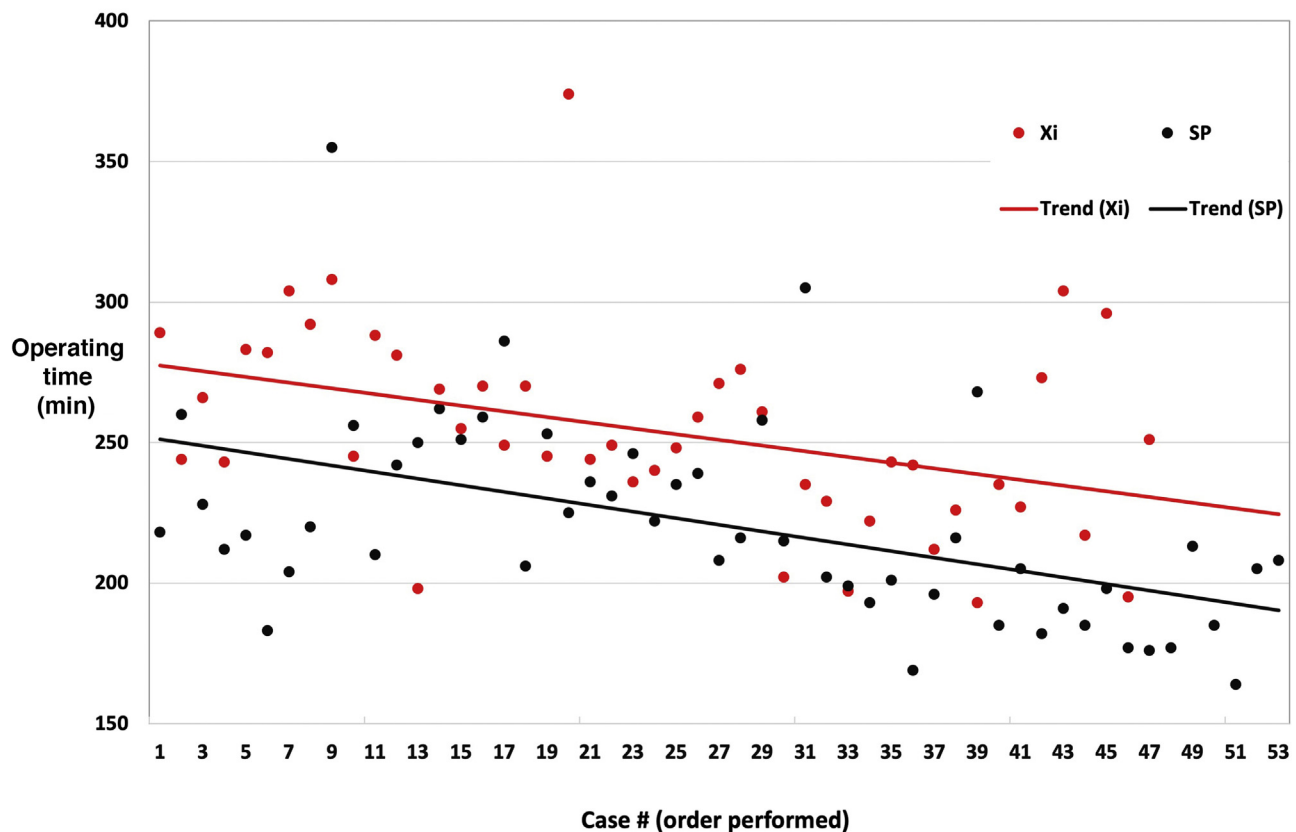


Fig. 1 – Operating time (Y axis) decreased over consecutive cases (X axis) for both Xi (red) and SP (black) primary penile inversion peritoneal flap vaginoplasties. The mean operating time was significantly shorter with the SP robot than with the Xi robot.

Table 3 – Complications.

Complications	Total	Xi system (n = 47)	SP system (n = 53)	p value
Intraoperative, n (%)	0 (0)	0 (0)	0 (0)	–
Transfusion, n (%)	6 (6)	5 (11)	1 (2)	0.010
Vaginal stenosis (<10.9 cm [2 dots] depth), n (%)	7 (7)	6 (13)	1 (2)	0.003
Acute urinary retention, n (%)	7 (7)	2 (4)	5 (9)	0.152
Rectovaginal fistula, n (%)	1 (1)	0 (0)	1 (2)	0.181
Bowel obstruction, n (%)	2 (2)	0 (0)	2 (4)	0.057
Reoperation (all causes), n (%)	13 (13)	7 (15)	6 (11)	0.453
Scar/stenosis, n		1	–	–
Bleeding/hematoma, n		1	1	–
Granulation, n		2	–	–
Cosmetic, n		1	2	–
Cyst/abscess, n		1	1	–
Urethral stenosis, n		1	1	–
Rectovaginal fistula, n		1	–	–
Bowel obstruction, n		–	1	–
Hernia, n		–	1	–

Table 4 – Postoperative outcomes.

Column 1	Total	Xi system (n = 47)	SP system (n = 53)	p value
Length of follow-up (d)	355.5	450.6	271.1	<0.001
Pelvic floor PT use, n (%)	37 (37)	11 (23)	26 (49)	<0.001
Vaginal depth (cm), mean	13.9	13.6	14.1	0.070
Vaginal width (cm), mean	3.7	3.7	3.7	0.040

PT = physical therapy.

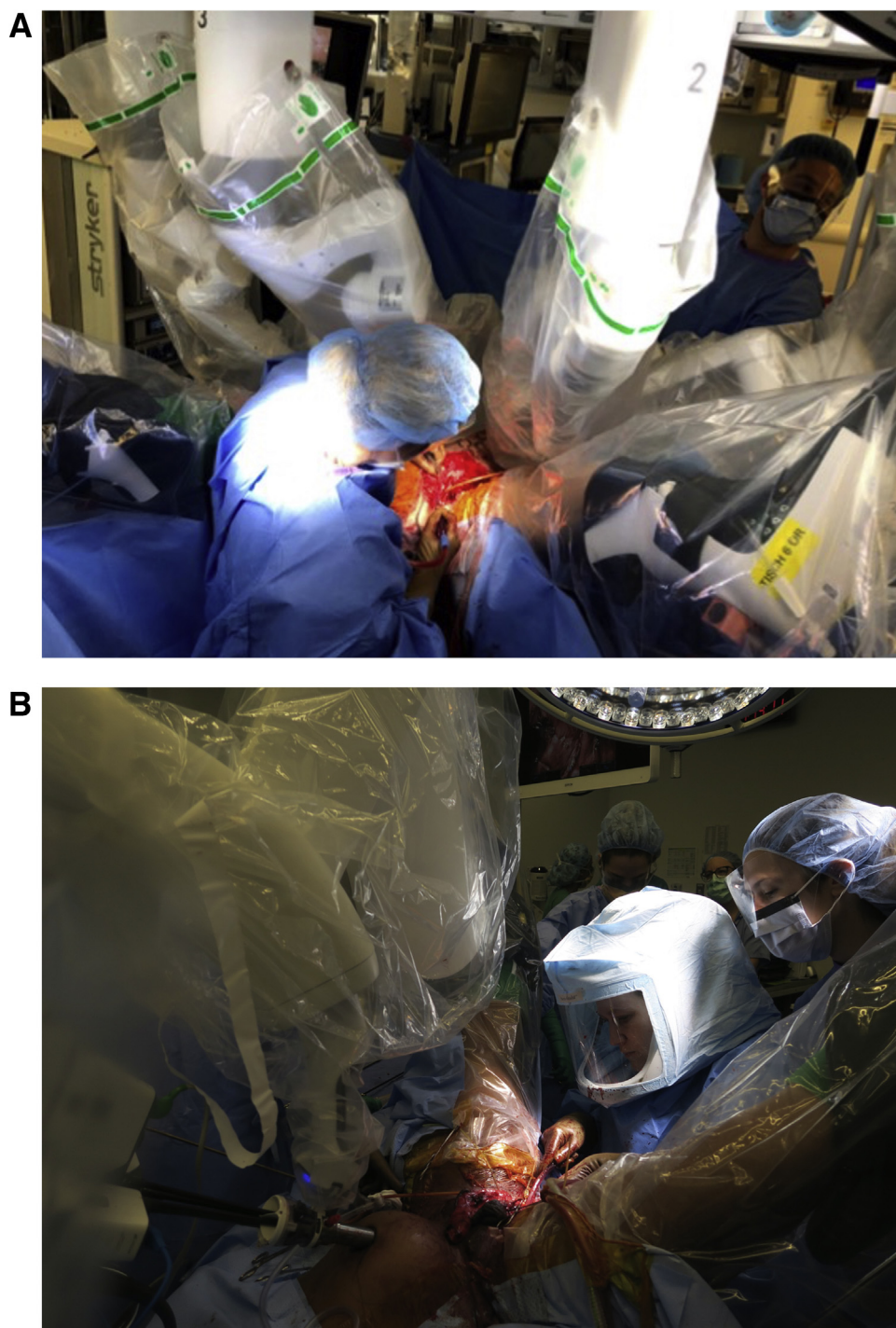


Fig. 2 – The Xi robotic arms overhang the perineum, impeding the progress of the perineal surgeon. (A) The SP robot does not impede (B) the perineal surgeon, facilitating simultaneous surgery.

separated peritoneal flap. There was no loss of bowel, and the patient recovered uneventfully. One patient developed a pelvic abscess presenting 5 wk postoperatively, with abdominal pain and fever. As the location of the abscess was not amenable to percutaneous drainage, laparoscopic drainage of the abscess was performed, and the patient was discharged 1 d later with complete resolution on antibiotics. Five patients experienced de novo urge incontinence. Two resolved spontaneously, two have mild incontinence improving with physical therapy, and one patient has ongoing two pads-per-day incontinence.

At a mean follow-up of 356 (range 179–761) d, vaginal depth and width were, respectively, 13.6 (range 9.7–14.5) and 3.7 (range 2.9–3.8) cm in the Xi group, and 14.1 (range 9.7–14.5) and 3.7 (range 3.5–3.8) cm in the SP group ($p=0.07$ for depth, $p=0.04$ for width; Table 4). Of the patients, 37% utilized pelvic floor physical therapy postoperatively for additional support with dilation.

4. Discussion

As more transgender women and nonbinary people seek gender-affirming vaginoplasty, continuous technical improvements must be made to accommodate new anatomic challenges in a diverse patient population. While RPGAV may be considered an alternative to traditional PIV in most vaginoplasty candidates, RPGAV is most beneficial when penile and scrotal skin are limited, such as from prior genital surgery or early pubertal blockade with resultant genital underdevelopment.

Although neovaginal stenosis can result from insufficient dilation postoperatively, tissue retraction from the apex and graft loss also contribute [4,6]. The primary benefit of RPGAV is creation of a well-vascularized neovaginal apex, especially when genital skin is limited. In addition, suturing of inverted penoscrotal tube to peritoneal flaps can reduce “prolapse” of the neovaginal lining.

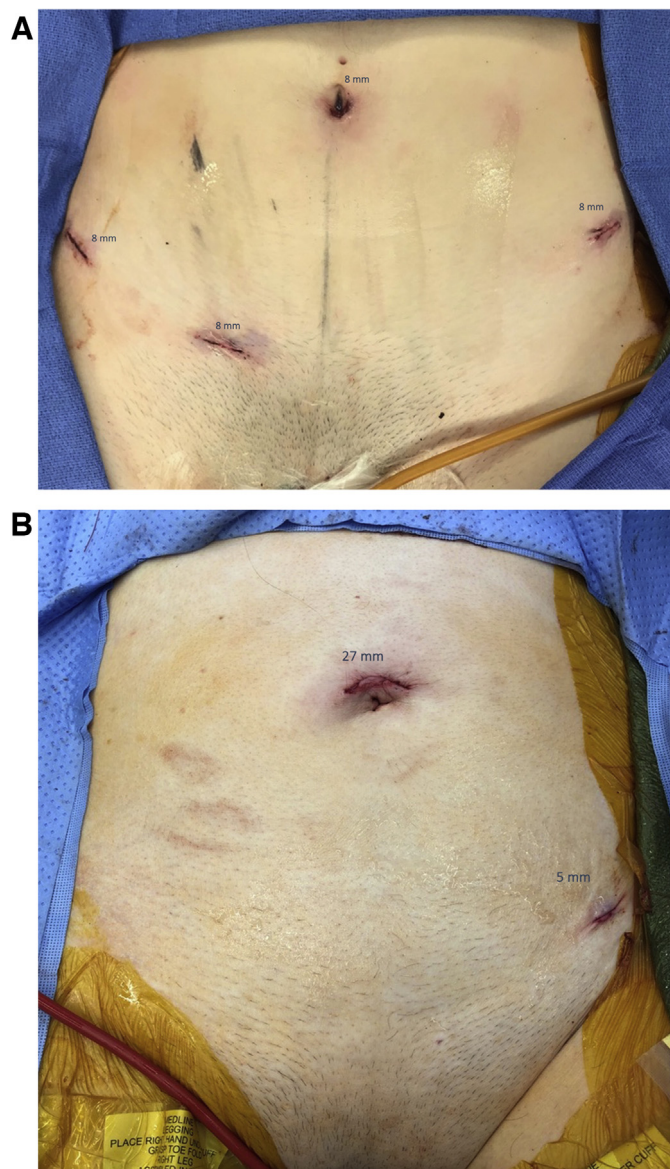


Fig. 3 – Typical port-site incisions for (A) the Xi robot versus (B) the SP robot. The SP trocar site is periumbilical for improved scar concealment.

When vaginal stenosis occurs, it tends to be a functional stenosis at the level of the pelvic floor rather than apical or anastomotic contracture. The first treatment for vaginal stenosis is pelvic floor physical therapy. If this fails, we perform an examination under anesthesia with dilation, as indicated. While revision surgery has not been needed, we would prefer repeat peritoneal flap vaginoplasty.

The use of urologic SP robot has been described for vaginoplasty and canal revision, radical cystectomy, pelvic lymph node dissection (PLND), radical prostatectomy with PLND, and ureteral reimplantation [7–12], with preliminary results showing safety and feasibility. SP RPGAV also appears to be safe and feasible. While the vaginal stenosis rate was lower in the SP group, it is likely a reflection of shorter follow-up time. Transfusions were more common in the Xi group, possibly attributable to early experience with RPGAV. Otherwise, there were no differences in intra- or postoperative complications between the Xi and SP groups. Vaginal depth was also equivalent between the two approaches.

There may be several benefits to using the SP robot in RPGAV, including decreased operative time, and improved surgeon visualization and mobility. In a procedure that can be performed efficiently with a perineal and robotic surgeon, the single arm of the SP system provides more room for the perineal surgeon to operate concurrently (Fig. 2). Fig. 1 displays the progressively decreasing operative duration for consecutive RPGAV. There was a decrease in operative time between the two modalities despite the surgical learning curve one might expect with using the new SP robot, as demonstrated in other operations [9]. Extended operative and lithotomy time are risk factors for positioning-related complications, such as neuropathy, which did not occur in our cohort [13,14]. Our mean operative time of 221 ± 36.1 min with the SP robot is comparable with the typical operative time for traditional PIV [15].

In our experience, the lateral arms of the Xi system tended to clash with the lateral walls of the canal as dissection deepens. As reported in other early series, we found that the configuration of SP instruments allowed for greater ease of working in a narrow space, with more degrees of freedom during deep dissection and intracorporeal suturing [9]. In addition, the articulating camera aided in canal dissection due to improved visualization. Additional follow-up is required to assess whether these surgeon-reported benefits impact surgical outcomes.

Cosmetically, patients may prefer the supraumbilical 5 mm lateral port-site incision over the four or five incisions required with the Xi robot (Fig. 3), as suggested in laparoendoscopic single-site studies [16]. However, abdominal incisions are absent in traditional PIV approaches unless abdominal skin graft is used, and data on patient perceptions of cosmesis are lacking.

RPGAV remains a relatively new procedure. While longer-term data are needed to assess stabilization of vaginal depth and later morbidity and complications, this represents the longest published follow-up of patients who have undergone RPGAV. Intra-abdominal complications

such as small bowel obstruction, peritoneal flap dehiscence and herniation, pelvic abscess, and rectovaginal fistula were rare, quickly identified, and treated. Although we have not experienced these complications to date, additional theoretical risks of RPGAV include peritonitis, intra-abdominal adhesions, and injury to the vasculature, ureters, and bladder. Additional risks include positioning-related neuropathies, port-site hernias, and equipment malfunction.

Costs of adopting new robotic surgical technology may be significant [17–19]. While the cost of the two robotic systems was not investigated in this study, any increase in costs may be offset by savings from decreased operative time and improved long-term outcomes. Further study is required in this matter.

This study has several limitations. Since all SP cases were performed after the Xi cohort was completed, surgical technique and efficiency refinements may account for some improvement in operative times between the two robotic systems; however, there is clear benefit for the perineal surgeon to operate concurrently due to decreased hindrance from the SP arm. Additionally, we lack patient-reported data on changes in gender dysphoria, satisfaction, sexual health, urinary outcomes, and cosmesis. We are able to demonstrate safety and feasibility of the technique, however. Ultimately, long-term data are needed to establish the complication rates and durability of RPGAV. These limitations notwithstanding, our study supports RPGAV using either XI or SP systems as a safe and feasible approach to feminizing genital reconstruction.

5. Conclusions

There is no significant difference in complications or postoperative vaginal depth between Xi or SP systems for RPGAV, a safe alternative to traditional PIV. The SP robotic system allows for shorter operative time in a two-surgeon approach.

Author contributions: Lee C. Zhao had full access to all the data in the study and takes responsibility for the integrity of the data and the accuracy of the data analysis.

Study concept and design: Zhao, Bluebond-Langner.

Acquisition of data: Zhao, Jun, Dy, Blasdel.

Analysis and interpretation of data: Zhao, Jun, Dy.

Drafting of the manuscript: Dy, Jun.

Critical revision of the manuscript for important intellectual content: Zhao, Jun, Dy.

Statistical analysis: Zhao, Jun, Dy.

Obtaining funding: None.

Administrative, technical, or material support: None.

Supervision: Zhao, Bluebond-Langner.

Other: None.

Financial disclosures: Lee C. Zhao certifies that all conflicts of interest, including specific financial interests and relationships and affiliations relevant to the subject matter or materials discussed in the manuscript (eg, employment/affiliation, grants or funding, consultancies, honoraria, stock ownership or options, expert testimony, royalties, or patents filed, received, or pending), are the following: Lee C. Zhao is a consultant for Intuitive Surgical, Inc. None of the other authors of this manuscript have

commercial associations or financial disclosures to report that create a conflict of interest with information presented in this manuscript.

Funding/Support and role of the sponsor: None.

Appendix A. Supplementary data

The Surgery in Motion video accompanying this article can be found in the online version at doi:<https://doi.org/10.1016/j.eururo.2020.06.040> and via www.europeanurology.com.

References

- [1] James S, Herman J, Rankin S, et al. The report of the 2015 US transgender survey. Washington, DC: National Center for Transgender Equality; 2016.
- [2] Canner JK, Harfouch O, Kodadek LM, et al. Temporal trends in gender-affirming surgery among transgender patients in the United States. *JAMA Surg* 2018;153:609–16.
- [3] Arcelus J, Bouman WP, Van Den Noortgate W, Claes L, Witcomb G, Fernandez-Aranda F. Systematic review and meta-analysis of prevalence studies in transsexualism. *Eur Psychiatry* 2015;30:807–15.
- [4] Horbach SE, Bouman MB, Smit JM, Özer M, Buncamper ME, Mullender MG. Outcome of vaginoplasty in male-to-female transgenders: a systematic review of surgical techniques. *J Sex Med* 2015;12:1499–512.
- [5] Jacoby A, Maliha S, Granieri MA, et al. Robotic Davydov peritoneal flap vaginoplasty for augmentation of vaginal depth in feminizing vaginoplasty. *J Urol* 2019;201:1171–6.
- [6] Rossi Neto R, Hintz F, Krege S, Rubben H, Vom Dorp F. Gender reassignment surgery—a 13 year review of surgical outcomes. *Int Braz J Urol* 2012;38:97–107.
- [7] Kaouk J, Bertolo R, Eltemamy M, Garisto J. Single-port robot-assisted radical prostatectomy: first clinical experience using the SP surgical system. *Urology* 2019;124:309.
- [8] Kaouk J, Garisto J, Bertolo R. Robotic Urologic surgical interventions performed with the single port dedicated platform: first clinical investigation. *Eur Urol* 2019;75:684–91.
- [9] Kaouk J, Garisto J, Eltemamy M, Bertolo R. Step-by-step technique for single-port robot-assisted radical cystectomy and pelvic lymph nodes dissection using the da Vinci® SP™ surgical system. *BJU Int* 2019;124:707–12. <http://dx.doi.org/10.1111/bju.14744>.
- [10] Kaouk JH, Garisto J, Eltemamy M, Bertolo R. Robot-assisted surgery for benign distal ureteral strictures: step-by-step technique using the SP((R)) surgical system. *BJU Int* 2019;123:733–9.
- [11] Dobbs RW, Halgrimson WR, Madueke I, Vigneswaran HT, Wilson JO, Crivellaro S. Single-port robot-assisted laparoscopic radical prostatectomy: initial experience and technique with the da Vinci((R)) SP platform. *BJU Int* 2019;124:1022–7.
- [12] Acar O, Sofer L, Dobbs RW, et al. Single port and multi-port approaches for robotic vaginoplasty with the Davydov technique. *Urology* 2020;138:166–73.
- [13] Koc G, Tazeh NN, Joudi FN, Winfield HN, Tracy CR, Brown JA. Lower extremity neuropathies after robot-assisted laparoscopic prostatectomy on a split-leg table. *J Endourol* 2012;26:1026–9.
- [14] Warner MA, Martin JT, Schroeder DR, Offord KP, Chute CG. Lower-extremity motor neuropathy associated with surgery performed on patients in a lithotomy position. *Anesthesiology* 1994;81:6–12.
- [15] Buncamper ME, van der Sluis WB, van der Pas RS, et al. Surgical outcome after penile inversion vaginoplasty: a retrospective study of 475 transgender women. *Plast Reconstr Surg* 2016;138:999–1007.
- [16] Park SK, Olweny EO, Best SL, Tracy CR, Mir SA, Cadeddu JA. Patient-reported body image and cosmesis outcomes following kidney surgery: comparison of laparoendoscopic single-site, laparoscopic, and open surgery. *Eur Urol* 2011;60:1097–104.
- [17] Barbash GI, Glied SA. New technology and health care costs—the case of robot-assisted surgery. *N Engl J Med* 2010;363:701–4.
- [18] Close A, Robertson C, Rushton S, et al. Comparative cost-effectiveness of robot-assisted and standard laparoscopic prostatectomy as alternatives to open radical prostatectomy for treatment of men with localised prostate cancer: a health technology assessment from the perspective of the UK National Health Service. *Eur Urol* 2013;64:361–9.
- [19] Williams SB, Prado K, Hu JC. Economics of robotic surgery: does it make sense and for whom? *Urol Clin North Am* 2014;41:591–6.